

This is an open-access article distributed under the terms of the Creative Commons Attribution License, which permits unrestricted use, distribution, and reproduction in any medium, provided the original author(s) and source are credited.



ISSN: 2167-7689

Pharmaceutical Regulatory Affairs: Open Access

**The International Open Access
Pharmaceutical Regulatory Affairs: Open Access**

Editor-in-Chief

George Perry

University of Texas at San Antonio, USA

Ji li

State University of New York, USA

Executive Editors

Michel S. Bourin

University of Nantes, France

Paola Minghetti

University of Milan, Italy

Hideharu Shintani

Chuo University, Japan

Available online at: OMICS Publishing Group (www.omicsonline.org)

This article was originally published in a journal published by OMICS Publishing Group, and the attached copy is provided by OMICS Publishing Group for the author's benefit and for the benefit of the author's institution, for commercial/research/educational use including without limitation use in instruction at your institution, sending it to specific colleagues that you know, and providing a copy to your institution's administrator.

All other uses, reproduction and distribution, including without limitation commercial reprints, selling or licensing copies or access, or posting on open internet sites, your personal or institution's website or repository, are requested to cite properly.

Digital Object Identifier: <http://dx.doi.org/10.4172/2167-7689.S12-001>

Research Article

Open Access

Death after Quadrivalent Human Papillomavirus (HPV) Vaccination: Causal or Coincidental?

Lucija Tomljenovic^{1*} and Christopher A Shaw^{1,2,3}¹Department of Ophthalmology and Visual Sciences, University of British Columbia, Canada²Program in Experimental Medicine, University of British Columbia, Canada³Program in Neuroscience, University of British Columbia, Canada

Abstract

Background: The proper understanding of a true risk from vaccines is crucial for avoiding unnecessary adverse reactions (ADRs). However, to this date no solid tests or criteria have been established to determine whether adverse events are causally linked to vaccinations.

Objectives: This research was carried out to determine whether or not some serious autoimmune and neurological ADRs following HPV vaccination are causal or merely coincidental and to validate a biomarker-based immunohistochemical (IHC) protocol for assessing causality in case of vaccination-suspected serious adverse neurological outcomes.

Methods: Post-mortem brain tissue specimens from two young women who suffered from cerebral vasculitis-type symptoms following vaccination with the HPV vaccine Gardasil were analysed by IHC for various immunoinflammatory markers. Brain sections were also stained for antibodies recognizing HPV-16L1 and HPV-18L1 antigen which are present in Gardasil.

Results: In both cases, the autopsy revealed no anatomical, microbiological nor toxicological findings that might have explained the death of the individuals. In contrast, our IHC analysis showed evidence of an autoimmune vasculitis potentially triggered by the cross-reactive HPV-16L1 antibodies binding to the wall of cerebral blood vessels in all examined brain samples. We also detected the presence of HPV-16L1 particles within the cerebral vasculature with some HPV-16L1 particles adhering to the blood vessel walls. HPV-18L1 antibodies did not bind to cerebral blood vessels nor any other neural tissues. IHC also showed increased T-cell signalling and marked activation of the classical antibody-dependent complement pathway in cerebral vascular tissues from both cases. This pattern of complement activation in the absence of an active brain infection indicates an abnormal triggering of the immune response in which the immune attack is directed towards self-tissue.

Conclusions: Our study suggests that HPV vaccines containing HPV-16L1 antigens pose an inherent risk for triggering potentially fatal autoimmune vasculopathies.

Practice implications: Cerebral vasculitis is a serious disease which typically results in fatal outcomes when undiagnosed and left untreated. The fact that many of the symptoms reported to vaccine safety surveillance databases following HPV vaccination are indicative of cerebral vasculitis, but are unrecognized as such (i.e., intense persistent migraines, syncope, seizures, tremors and tingling, myalgia, locomotor abnormalities, psychotic symptoms and cognitive deficits), is a serious concern in light of the present findings. It thus appears that in some cases vaccination may be the triggering factor of fatal autoimmune/neurological events. Physicians should be aware of this association.

Keywords: HPV vaccines; Serious adverse reactions; Cerebral vasculitis; Vasculopathy; Autoimmunity; Molecular mimicry; Immune complexes; Autoantibodies

Introduction

In the past several decades, there have been numerous studies and case reports documenting neurological and autoimmune adverse reactions (ADRs) following the use of various vaccines. Arthritis, vasculitis, systemic lupus erythematosus (SLE), encephalopathy, neuropathy, seizure disorders and autoimmune demyelinating disease syndromes are the most frequently reported serious adverse events [1-13]. Although a clear temporal relationship between the administration of a vaccine and the adverse event is sometimes observed, in the vast majority of cases no causal connection can be demonstrated. Thus, it is often concluded that, (i) the majority of serious ADRs that occur post-vaccination are coincidental and unrelated to the vaccine [14] and, (ii) true serious vaccine-related ADRs (i.e., permanent disability and death) are extremely rare [15]. There are however several important reasons why causality is rarely established with regard to vaccination-associated ADRs. These include: the criteria for causality are poorly defined [6,16,17]; the latency period between vaccination and autoimmunity can range from days to years (individuals' susceptibility factors most

likely playing a role in determining the temporal onset, time course, and severity of symptoms) [6]; neurological outcomes, as in other neurological disorders may take considerable periods to manifest as obvious pathology [18]; post-vaccination adverse manifestations can be atypical and might not be compatible with a defined autoimmune or neurological disease [6]; individual susceptibility factors are not considered and a "one-size fits all" principle is assumed [19]; a triggering role of the vaccine in the adverse outcome is not considered [20].

***Corresponding author:** Lucija Tomljenovic, Neural Dynamics Research Group, 828 W. 10th Ave., Vancouver, BC, Canada, V5Z 1L8, Tel: 604-875-4111 (ext. 68375); Fax: 604-876-4376; E-mail: lucijat77@gmail.com

Received September 13, 2012; **Accepted** October 02, 2012; **Published** October 04, 2012

Citation: Tomljenovic L, Shaw CA (2012) Death after Quadrivalent Human Papillomavirus (HPV) Vaccination: Causal or Coincidental? Pharmaceut Reg Affairs S12:001. doi:10.4172/2167-7689.S12-001

Copyright: © 2012 Tomljenovic L, et al. This is an open-access article distributed under the terms of the Creative Commons Attribution License, which permits unrestricted use, distribution, and reproduction in any medium, provided the original author and source are credited.

Quadrivalent human papillomavirus (qHPV) vaccine Gardasil was licensed in 2006 by the U.S. Food and Drug Administration (FDA) following a fast track approval process [21]. In pre- and post-licensure epidemiological studies no autoimmune safety concerns associated with Gardasil vaccination were identified [22,23] and the vaccine has been considered to have a remarkably good safety profile [24]. However, a careful scrutiny of Gardasil safety trials shows evidence of significant flaws in study design, data reporting and interpretation [25-28]. Irrespective of these latter observations, it is important to note that epidemiological studies only test for “association” and not “causation”, thus providing unreliable estimates of true risks. On the other hand, data from numerous case reports documenting serious autoimmune and neurological complications following HPV vaccination continue to raise concerns [11,12,29-35]. Nonetheless, the precise etiology of these post-HPV vaccination associated phenomena has been elusive and hence causality remains unascertained.

We have recently developed an immunohistochemical (IHC) protocol based on analyzing two cases of sudden and unexplained death following vaccination with the qHPV vaccine Gardasil. This protocol has been developed for the purpose of determining whether the serious autoimmune and neurological manifestations reported following HPV vaccination are causal or merely coincidental.

Patients and Methods

Case 1

A 19-year-old female without a relevant medical history and taking no drugs expired in her sleep, approximately 6 months after her third and final qHPV vaccine booster and following exacerbation of initial vaccination-related symptoms. She had last been seen alive by her parents the previous evening. Her symptoms started after the first qHPV injection when she developed warts on her hand that persisted throughout the vaccination period. In addition, she suffered from unexplained fatigue, muscle weakness, tachycardia, chest pain, tingling in extremities, irritability, mental confusion and periods of amnesia (memory lapses). The autopsy was unremarkable and failed to determine the exact cause of death. Internal examination revealed some minor changes involving the gallbladder and the uterine cervix (both of which on further examination by microbiological studies and histology revealed no significant disease). After a full autopsy no major abnormality was found anatomically, microbiologically or toxicologically that might have been regarded as a potential cause of death. Histological analysis of the brain hippocampus, cerebellum and watershed cortex allegedly revealed no evidence of neuronal loss or neuroinflammatory changes. However, the autopsy report did not specify which immune antibodies and stains were used for histological investigations.

Case 2

A 14-year-old female with a previous history of migraines and oral contraceptive use developed more severe migraines, speech problems, dizziness, weakness, inability to walk, depressed consciousness, confusion, amnesia and vomiting 14 days after receiving her first qHPV vaccine injection. These symptoms gradually resolved. However, 15 days after her second qHPV vaccine booster she was found unconscious in her bathtub by her mother 30 minutes after she had entered the bathroom to have a shower. Emergency help was summoned and arrived quickly. Resuscitation efforts were attempted. The paramedic noted that the patient was found without a pulse. Upon arrival at the hospital and approximately 30 minutes later, the patient suffered

cardiac arrest. Resuscitation was terminated approximately 40 minutes later and the patient was pronounced dead.

Similar to Case 1, the autopsy failed to identify a precise cause of death. In particular, there were no anatomical, microbiological nor toxicological findings that could explain this case of death which was classified as “sudden and unexpected death”. Nonetheless, autopsy revealed cerebral edema and cerebellar herniation indicative of a focally disrupted blood-brain barrier. Although no specific antibodies to inflammatory markers were used in IHC analysis of brain sections, the autopsy reported that there was no evidence of inflammatory processes or microglial reactions in the patient’s brain. There were however acidophilic changes of the Purkinje cells in the cerebellum with vacuolation of the overlying molecular layer. According to the coroner, these changes were consistent with terminal ischemic-hypoxic encephalopathy. Neuropathological examination did not demonstrate an underlying structural brain disorder. In addition, the coroner’s report commented that the ischemic-hypoxic encephalopathy was terminal as was the cerebral edema and that either one could have been caused by the other. Based on the autopsy findings, the coroner was unable to establish a precise sequence of events and the specific etiology remained undetermined.

Tissue samples

Paraffin-embedded brain tissue specimens collected at autopsy from the two cases described above were used in this study. The tissues analyzed by IHC included the cerebellum, hippocampus, choroid plexus and watershed cortex (Case 1), and cerebellum, hippocampus, choroid plexus, portions of the brainstem (medulla, midbrain, pons), right basal ganglia, right parietal and left frontal lobes (Case 2). Sections were cut at 5 µm and mounted on glass slides.

IHC procedures

The paraffin brain sections were dewaxed, rehydrated and incubated for 15 min in methanol containing 3% H₂O₂ to block endogenous peroxidase activity. The sections were then incubated in 1% saponin in 1xPBS for 1 hr at room temperature (RT) and subsequently pre-treated by boiling for 20 min in an appropriate antigen retrieval solution (Table 1) to facilitate antigen retrieval and to increase membrane permeability to primary antibodies (Abs). The sections were then blocked in 1xPBS containing 0.1% Tween and 10% normal goat serum for 1hr at RT. Following the blocking step, the sections were incubated with appropriate dilutions of the primary Ab in the blocking solution (Table 1) overnight at 4°C in a humidified chamber.

Subsequently, sections were rinsed three times in 1xPBS and incubated with biotinylated, affinity-purified anti-immunoglobulin G (IgG) secondary Ab at 1:200 dilution (Vector Labs, Inc), and then with the avidin-biotin complex (ABC)-immunoperoxidase Vectastain Elite ABC kit (Vector Laboratories, Burlingame, Calif). The positive reaction was visualized by 3,3'-diaminobenzidine (DAB) peroxidation according to standard methods. The sections were counterstained with methyl green, dehydrated, coverslipped, and observed on a Zeiss Axiovert microscope (Carl Zeiss Canada Ltd., Toronto, ON) connected to a computerized system with a photo camera. Images at 10x and 40x magnification were captured using AxioVision 4.3 software.

Results and Discussion

Principal findings

The results from our IHC examinations of brain tissue specimens from two young women who died following vaccination with the

Antibody	Type	Epitope/Specificity	Pre-treatment/antigen retrieval	Dilution	Source
C1q	Monoclonal, Anti-human	Complement, classical pathway	0.25 mM EDTA buffer pH 9.0	1:100	Abcam
C5b-9	Polyclonal, Anti-human	Complement, membrane attack complex	0.1 M Citric Acid buffer pH 6.0	1:100	Abcam
IgG, IgM, IgA	Polyclonal, Anti-human	Immunoglobulin complexes	0.1 M Citric Acid buffer pH 6.0	1:100	Dako
HPV-16L1	Monoclonal, Anti-HPV-16	HPV-16 major capsid protein L1	0.1 M Citric Acid buffer pH 6.0	1:200	Abcam
HPV-18L1	Monoclonal, Anti-HPV-18	HPV-18 major capsid protein L1	0.1 M Citric Acid buffer pH 6.0	1:100	Abcam
HLA-DR (MHC II)	Monoclonal, Anti-human	Major histocompatibility complex class II	0.1 M Citric Acid buffer pH 6.0	1:100	Dako
CD3	Polyclonal, Anti-human	T-cell lymphocytes	0.25 mM EDTA buffer pH 9.0	1:100	Dako
MMP-9	Polyclonal, Anti-human	Matrix metalloproteinase 9	0.1 M Citric Acid buffer pH 6.0	1:100	Abcam
GFAP	Monoclonal, Anti-mouse/human	Reactive astrocytes	0.1 M Citric Acid buffer pH 6.0	1:200	Calbiochem
Iba-1	Polyclonal, Anti-mouse/human	Activated microglia	0.1 M Citric Acid buffer pH 6.0	1:500	Wako

Table 1: Panel of primary antibodies used in the study.

qHPV vaccine Gardasil showed strong evidence of an autoimmune vasculitis triggered by the cross-reactive HPV-16L1 antibodies binding to the wall of cerebral blood vessels (Figures 1 and 2). In addition, there was clear evidence of the presence of HPV-16L1 particles within the cerebral vasculature with some HPV-16L1 particles adhering to the blood vessel walls (Figures 1C, 2C and 2D). In contrast, HPV-18L1 antibodies did not bind to cerebral blood vessels nor any other neural tissues (Figure 1D).

Histopathologically, immune-mediated vasculitis is typified by excessive recruitment and vascular adhesion of T lymphocytes, increased complement and MHC II signaling and complement-dependent deposition of immunoglobulin G-immune complexes to cerebral vasculature [5,36-40]. Increased expression of proteolytic matrix metalloproteinases (MMPs) also characterizes immune vasculopathic syndromes [41-43]. The MMPs play a major role in both the progression of inflammatory infiltrates and vessel destruction [41-43]. The ensuing vascular damage is manifested in hemorrhagic and ischemic brain tissue lesions. Notably, there was clear and consistent evidence of all these pathogenic immune processes in the brain tissue specimens from both young women (Figures 3-8).

The finding of HPV-16L1 particles in cerebral blood vessels and adhering to the wall of these vessels in brain tissue specimens from both cases (Figures 1,2,5 and 6) is of significant concern as it demonstrates that vaccine-derived immune complexes are capable of penetrating the blood-brain barrier. Gardasil is a recombinant vaccine and contains virus-like particles (VLPs) of the recombinant major capsid (L1) protein of HPV types 6, 11, 16, and 18 as active substances (note that the bivalent HPV vaccine Cervarix contains only HPV-16L1 and HPV-18L1 VLPs). The HPV VLPs in Gardasil (including HPV-16L1), are adsorbed on amorphous aluminium hydroxyphosphate sulfate adjuvant and recent studies in animal models show that aluminum adjuvant nanoparticles, taken up by monocytes after injection, first translocate to draining lymph nodes, then travel across the blood-brain barrier and eventually accumulate in the brain where they may cause significant immune-inflammatory adverse reactions [44]. Thus, the presence of HPV-16L1 particles in cerebral vasculature in brain tissue specimens from both young women vaccinated with Gardasil may be explained by a “Trojan horse” mechanism dependent on circulating macrophages by which these particles adsorbed to aluminum adjuvant gain access to brain tissue.

It should also be noted that accumulation of immune complexes

and immune cells in brain tissues does not normally occur unless there is either: 1) a direct brain infection, 2) brain trauma or alternatively, 3) an excessive stimulation of the immune system, such as through vaccination. It would appear from the autopsy results and the medical histories (see Methods) that only the latter applies in both cases described.

The finding of a cerebral edema following autopsy in Case 2 is strongly suggestive of a focal blood-brain barrier breakdown [10,45]. Additionally, H&E staining showed clear evidence of hemorrhages (Figure 8), which were also present in Case 1 (Figure 7). Disruption of the blood-brain barrier manifesting in hemorrhagic tissue lesions could have resulted from both vasculitis and deleterious effects of excessive levels of glia-derived inflammatory cytokines. Although the autopsy failed to show evidence of microglial and inflammatory reactions in both cases, this was likely because no glia-specific markers were used in the histopathological analyses of brain tissue specimens. In contrast, results from our IHC analysis using micro- and astroglia specific markers (Table 1) showed exceptionally intense micro- and astrogliosis in all brain tissue sections examined from both Case 1 and Case 2 (Figures 9 and 10). Microglia are the brain’s resident immune cells and their excessive activation can lead to irreversible neurodestructive and pro-inflammatory processes in the brain [46,47].

It is also well known that activated microglia increase the permeability of the blood-brain barrier to other inflammatory factors and to trafficking lymphocytes [48]. Moreover, microglial aggregation in the brain is also recognized as a marker for hypoxic-ischemic brain injury [49], the latter diagnosed by the coroner in Case 2. Both microglia and astroglia are activated by a variety of immune insults, including aluminum vaccine adjuvants which are present in both HPV vaccines Gardasil and Cervarix. In addition, animal experiments show that only two injections of aluminum adjuvants at concentrations comparable to those used in human vaccines are sufficient to cause highly significant activation of the microglia that persists up to 6 months post-injection [50].

Autoimmune vasculitis and vaccinations

Vasculitis encompasses heterogeneous disorders whose central feature is inflammatory destruction of the blood vessel wall with resultant hemorrhagic lesions and tissue ischemia. Brain edemas may also be present due to compromised integrity of the cerebral vasculature [36,38,51-53]. Because involvement of blood vessels is intrinsic to

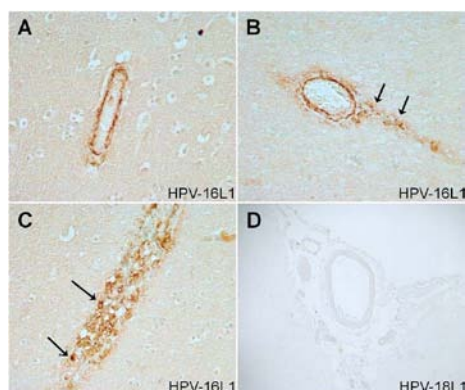


Figure 1: Case 1. Vascular immunostaining with anti-HPV-16L1 (A-C) and anti-HPV-18L1 antibodies (D). Vascular wall of two small blood vessels in the watershed cortex showing positive immunoreactivity for virus-like particles (VLPs) of the recombinant major capsid (L1) protein of HPV-16 (A,B). Note that some HPV-16L1 particles have infiltrated the brain tissue parenchyma adjacent to the vessel (B, arrows). Intravascular accumulation of HPV-16L1 VLPs in the watershed cortex (C). Note that some HPV-16L1⁺ cells are adhering to the endothelial lining of the vessel wall (C, arrows). Lack of HPV-18L1 immunoreactivity in the watershed cortex (D). HPV-18L1 immunoreactivity was also absent in other brain tissue specimens from both Case 1 and Case 2 (not shown). Magnification 40x.

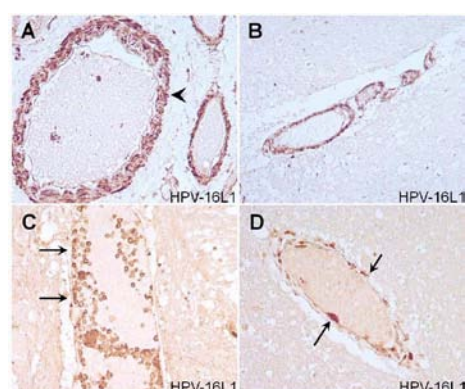


Figure 2: Case 2. Vascular wall of a large artery in the choroid plexus (A) showing positive immunoreactivity for HPV-16L1 in the vascular smooth muscle cell layer (arrowhead). Vascular wall of a small artery in the medulla showing positive immunoreactivity for HPV-16L1 (B). Intravascular accumulation of HPV-16L1 VLPs in the pons (C). Note that some HPV-16L1⁺ cells are adhering to the endothelial lining of the vessel wall (C, arrows). Vascular endothelial wall deposition of HPV-16L1 particles in the left frontal lobe (D, arrows). Magnification 40x.

inflammation of various types, vasculitis may underlie diverse diseases, making its diagnosis difficult [37,39]. Vasculitis can affect blood vessels including arteries and veins of all sizes in all areas of the body, resulting in a variety of clinical neurological manifestations [37,39].

The brain is particularly sensitive to ischemia. Vasculitis of the nervous system is thus of paramount importance to clinicians as it almost inevitably leads to permanent injury and disability when unrecognized and left untreated [37]. Cerebral vasculitis is thought to be rare [40]. However, because clinical presentation of cerebral vasculitis is highly variable with fluctuating signs and symptoms [40], and because it frequently underlies many diverse inflammatory diseases (i.e., SLE [41] and bacterial meningitis [43]), it is probable that many cases of cerebral vasculitis remain undiagnosed and/or misdiagnosed. Typical symptoms of cerebral vasculitis include severe headaches, orthostatic dizziness, syncope, seizures, tremors and tingling, weakness,

locomotor deficits, cognitive and language impairments [39,51,52]. Note that the vast majority of these symptoms were experienced by both Case 1 and Case 2 post- qHPV vaccination (Table 2).

Vasculitis has long been recognized as a possible severe ADR to vaccination [5,54-57]. For example, Carvalho and Shoenfeld described a case of polyarteritis nodosa, a rare, life-threatening, necrotizing vasculitis that affects medium-sized arteries following the administration of the hepatitis B vaccine in a 14-year-old boy who had no relevant previous history and who was not taking any drugs [5]. There have been numerous other case reports of vasculitis post-hepatitis B vaccination. In IHC examinations of these cases, no virus B antigen was detected in the blood vessels and no proof of cause and effect was established [55,57]. However, the possibility that the vaccine-derived hepatitis B antigen might have caused autoimmunity by molecular mimicry was not investigated. In fact, to the best of our knowledge, our study is the first to show direct evidence of a vaccine antigen-induced autoimmune vasculitis in the human central nervous system (CNS).

It is worth emphasizing that molecular mimicry (whereby the vaccine antigen resembles a host antigen) is generally accepted as a mechanism by which vaccines can trigger autoimmune diseases. Thus,

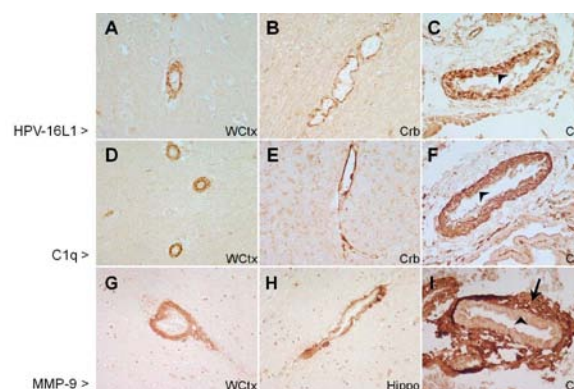


Figure 3: Case 1. Vascular walls of various types of blood vessels showing positive immunoreactivity for HPV-16L1 (A-C), C1q (D-F) and matrix metalloproteinase (MMP)-9 (G-I). Note that all three markers show positive immunoreactivity in the vascular smooth muscle cell layer (arrowheads) although MMP-9 is less prominent. The MMP-9 immunoreactivity is however very prominent in the extracellular matrix (arrow). WCtx=watershed cortex; Crb=cerebellum; Hippo=hippocampus; CP=choroid plexus. Magnification 40x.

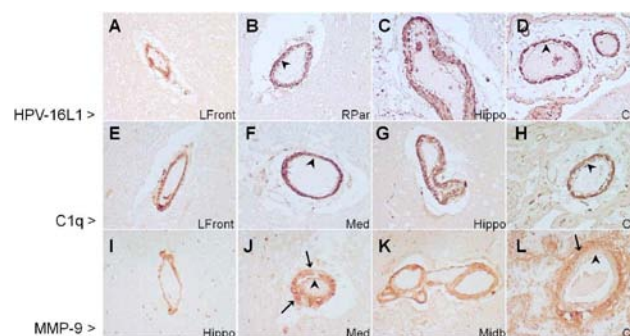


Figure 4: Case 2. Vascular walls of various types of blood vessels showing positive immunoreactivity for HPV-16L1 (A-D), C1q (E-H) and MMP-9 (I-L). Note that all three markers show positive immunoreactivity in the vascular smooth muscle cell layer (arrowheads), although MMP-9 is less prominent. The MMP-9 immunoreactivity is however very prominent in the extracellular matrix (arrow). LFront=left frontal lobe; RPar=right parietal lobe; Hippo=hippocampus; Med=medulla; Midb=midbrain; CP=choroid plexus. Magnification 40x.

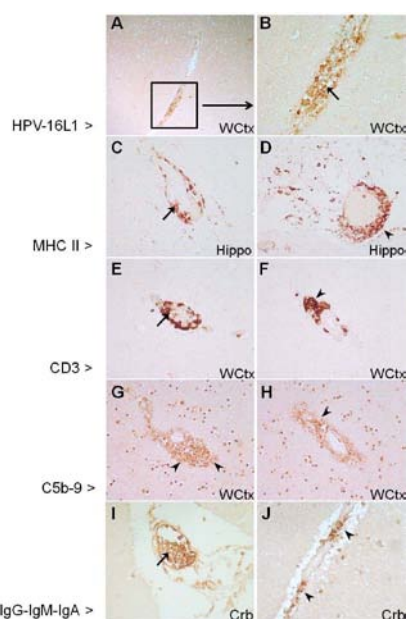


Figure 5: Case 1: Vascular (arrows) and perivascular (arrowheads) accumulation of HPV-16L1 (A,B), MHC class II (C,D), CD3 (E,F), C5b-9 (G,H) and IgG-IgM-IgA (I,J) positive cells. WCtx=watershed cortex; Hippo=hippocampus; Crb=cerebellum. Magnification 10x (A) and 40x (B-J).

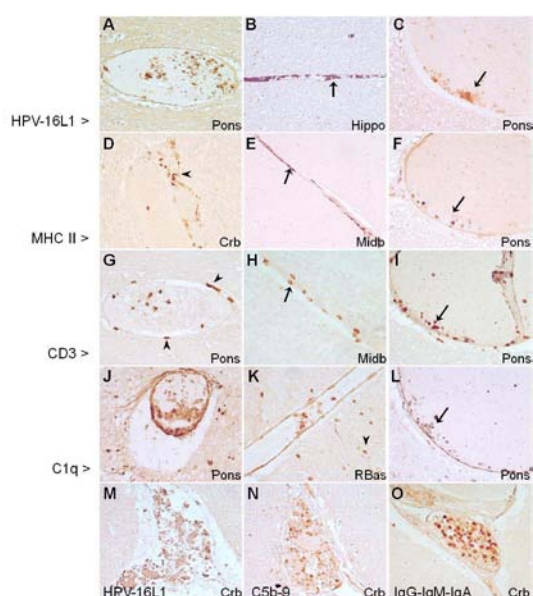


Figure 6: Case 2: Vascular accumulation of HPV-16L1 (A-C,M), MHC class II (D-F), CD3 (G-I), C1q (J-L), C5b-9 (N) and IgG-IgM-IgA (O) positive cells. Note the consistent pattern of HPV-16L1, MHC II, CD3 and C1q immunostaining (A-L), where majority of immunopositive cells are found adhering to the walls of cerebral blood vessels (arrows). Some MHC II⁺ cells (D, arrowhead) and CD3⁺ T cells are also found in the perivascular rim (G, arrowhead) and some C1q⁺ cells are infiltrating deep into the brain parenchyma adjacent to the vessel (K, arrowheads). Note the dense accumulation of HPV-16L1 (M), C5b-9 (N) and IgG-IgM-IgA (O) immunopositive cells in the cerebellar blood vessels. Hippo=hippocampus; Crb=cerebellum; Midb=midbrain; RBas=right basal ganglia. Magnification 40x.

antibodies and T cells that are produced to destroy the vaccine antigen also attack structurally similar self-antigens in different tissues (i.e., the wall of blood vessels) [5,6,35]. The fact that vaccination is often intended to prevent a disease and thus carried out in the absence of an active

infection in the host, implies that the risk of autoimmunity may be exacerbated if there is structural similarity between the vaccine antigen and the host tissue. The reason for this is two-fold. Firstly, vaccination produces a much higher and sustained level of antibodies compared to natural infection (i.e., Gardasil-induced HPV-16 antibody titers are 10-fold higher than natural HPV infection titers [58]). Secondly, in the absence of an actual infectious agent (i.e., HPV-16 virus), the vaccine-induced antibodies are likely to preferentially bind to host antigens.

Vasculitis and HPV vaccination

Recently two cases of vasculitis affecting young teenage girls following HPV vaccination have been reported. In both cases there was no history of preceding infection, and the strong temporal relationship between the administration of the bivalent HPV vaccine (Cervarix) and the development of vasculitis was notable [32].

Our search of the Vaccine Adverse Event Reporting System (VAERS) internet database [59] revealed numerous reports of post-HPV vaccination-associated vasculitis. An analysis of these cases shows that post-vaccination vasculitis-related symptoms most typically manifest within the first three to four months of vaccination (Table 3), as was also reported in Case 1 and Case 2 described herein. Moreover, we noted a striking similarity between the vasculitis-related symptoms reported to VAERS and those experienced by Case 1 and Case 2 (Table 2). Although a report to a passive vaccine safety surveillance system such as VAERS does not by itself prove that the vaccine caused an ADR, it should be noted that many VAERS reports also include detailed records of diagnostic laboratory analyses and clinician's follow-ups and their expert diagnosis. Notably, some of these reports include medically confirmed cases where the diagnosis of immune-mediated vasculitis was ascertained (i.e., VAERS ID# 425345-1, 436679-1; Table 3).

The precise etiology and the role of HPV vaccination in vasculitis cases reported to VAERS remained undetermined. However, we note that the histopathological examinations when conducted were very limited in scope (Table 3). Specifically, the possibility of HPV vaccine-induced autoimmunity via molecular mimicry due to cross reactivity between vaccine antigens and host vascular structures was neither investigated nor considered. The reason for such omissions in histopathological analyses of vaccine-suspected autoimmune pathologies is unclear, especially since medical scientists generally

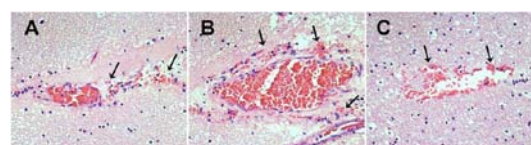


Figure 7: Case 1. Hematoxylin & Eosin (H&E) stain of blood vessels in the cerebellum (A), and the watershed cortex (B,C) showing hemorrhages. Note the presence of red blood cells in the brain tissue parenchyma adjacent to the blood vessels indicating brain tissue hemorrhage (arrows). Magnification 40x.

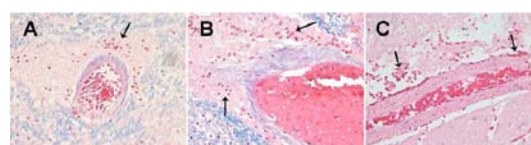


Figure 8: Case 2. Hematoxylin & Eosin (H&E) stain of arteries in the medulla (A), hippocampus (B) and the right basal ganglia (C) showing hemorrhages. Note the presence of red blood cells in the brain tissue parenchyma adjacent to the blood vessels indicating brain tissue hemorrhage (arrows). Magnification 40x.

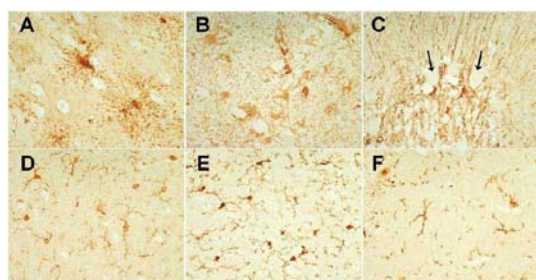


Figure 9: Case 1. Reactive astroglia visualized by the immunostaining with the anti-glial fibrillary acidic protein (GFAP) antibody in the watershed cortex (A) and the hippocampus (B). Increased immunoreactivity of Bergmann's astroglia around Purkinje cells (arrows) in the cerebellum (C). Reactive microglia visualized by the immunostaining with the anti-ionized calcium binding adaptor molecule 1 (Iba-1) antibody in the watershed cortex (D), hippocampus (E) and the cerebellum (F). Magnification 40x.

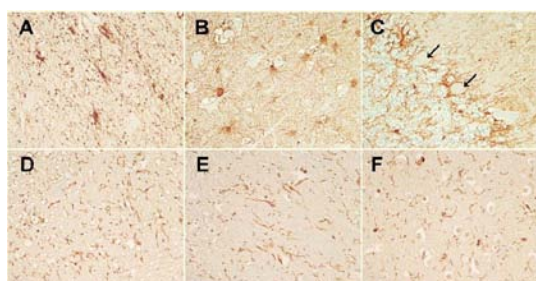


Figure 10: Case 2. Reactive astroglia visualized by the immunostaining with the anti-GFAP antibody in the midbrain (A) and the hippocampus (B). Increased immunoreactivity of Bergmann's astroglia around Purkinje cells (arrows) in the cerebellum (C). Reactive microglia visualized by the immunostaining with the anti-Iba-1 antibody in the pons (D), medulla (E) and hippocampus (F). Magnification 40x.

accept molecular mimicry as a plausible mechanism by which vaccines may trigger autoimmune diseases [5,6,35].

The pathophysiology of autoimmune vasculitis in light of present findings

Although most types of vasculitis are associated with immunologic abnormalities, the primary immunopathogenic events that initiate vascular inflammation and ensuing vascular damage are still far from clear. Nonetheless, it is recognized that the generation of auto-antibodies and deposition of immune complexes in vascular tissues play a central role in immune vasculopathies [39,60,61]. As shown in Figures 1-6, there appears to be clear evidence of both of these immunopathogenic processes in brain tissue specimens from both cases reported herein. Namely, numerous HPV-16L1 positive cells are found adhering to the walls of cerebral vessels and additionally, the vascular wall itself shows remarkably prominent immunoreactivity for HPV-16L1 (Figures 1-6).

Circulating immune complexes can result from either, response to infection, tissue injury or vaccination. The fact that vaccines are designed to hyper-stimulate antibody production (thus producing much higher antibody levels than what occurs following natural infection), suggests that vaccination may carry a much higher risk for immune vasculopathies. As noted above, Gardasil induces sustained antibody titers for HPV-16 that are more than 10-fold higher than natural HPV infection titers [58]. Notably, elevated levels of circulating immune complexes are typically observed in human vasculitis syndromes [61].

Deposition of immune complexes is a potent and rapid trigger for inducing vascular inflammation as it has the capacity to activate the complement pathway [5,39,53,61-63]. Indeed, inappropriate activation of the complement (i.e., in neurons and cerebral vasculature) is frequently observed in inflammatory neurodegenerative and neuroimmune diseases with underlying vascular dysfunction [53,61,63,64]. In particular, activation via the classical antibody-dependent complement pathway has long been recognized in immune complex-mediated diseases including vasculitis and SLE [37,39,65].

Vascular deposition of immune complexes and leukocyte recruitment to the vascular wall are themselves dependent on activation of the antibody-dependent complement pathway. In particular, abnormal expression of C1q by the vascular smooth muscle cells and vascular endothelium facilitates binding of T-lymphocytes and immune complexes to the vascular wall, resulting in vascular damage, ischemic lesions and brain edemas [53,62,66]. The demonstration of the crucial role of C1q activation in secondary brain edema due to compromised cerebral vasculature [53] is of particular relevance to Case 2 described in this report, where cerebral edema with bilateral uncal notching and early cerebellar tonsillar herniation was revealed on autopsy. Moreover, the autopsy of Case 2 also revealed ischemic changes affecting the Purkinje cells in the cerebellum which, according to the coroner's report, were indicative of a terminal ischemic-hypoxic encephalopathy.

It has further been demonstrated that both vascular endothelial and smooth muscle cells express MHC II and thus by facilitating T-cell recruitment essentially operate as competent antigen-presenting cells [36,67,68]. In this regard it is important to note that lymphocyte trafficking through the CNS is normally limited and that lymphocyte adhesion to brain endothelium is very low (less than 5% compared with 15%-20% in other organs) [39]. Furthermore, although cerebral vascular endothelial cells are capable of expressing MHC class I and II molecules (which are crucial for antigen presentation to the T lymphocytes), this occurs less often than in endothelium of the systemic vasculature [39].

Thus, the prominent and consistent HPV-16L1, Ig-complex, CD3⁺ T-cell, MHC II, C5b-9 and C1q vascular staining patterns in the brain tissue specimens described here (Figures 3-6), strongly point to a vasculitic neuropathy, triggered by an aberrant hyper-active immune response, as a plausible explanation for the fatal outcomes post-HPV vaccination in these two cases. Specifically, all six markers prominently stain numerous immune cells adhering to the walls of cerebral blood vessels (Figures 1-6). In addition, C1q and HPV-16L1 prominently stain the vascular endothelium and smooth muscle cell layer (Figures 3 and 4). Collectively, these findings suggests the involvement of both immune complexes and cross-reactive HPV-16L1 antibodies (binding to vascular walls) in triggering vascular damage.

The dense and prominent immunoreactivity for the membrane attack complex (MAC) component C5b-9 in perivascular deposits (Figure 5) provides further corroborative evidence for a vasculopathy resulting from an abnormal activation of the classical antibody-dependent complement pathway. The formation of MAC is a terminal step in the classical pathway and its activation results in a lytic destruction of target cells [64,69]. In immune vasculopathies, C5b-9/MAC activity is associated with destruction of both perivascular tissues and cells within the vessel wall [37,39]. MAC is normally activated by immune triggers, including vaccinations [70,71]. Activation of MAC in the brain in the absence of an active brain infection due to an

Cerebral vasculitis-associated symptoms reported to VAERS post-HPV vaccination	Case 1	Case 2
Neurological		
Migraines, headaches	+	+
Weakness, lack of coordination	+	+
Inability to walk	-	+
Inability to speak, memory lapses	+	+
Psychotic symptoms (anxiety, irritability, mental confusion)	+	+
Seizures, tremors, tingling	+	-
Syncope (loss of consciousness), dizziness	+	+
Systemic		
Fatigue and nausea	+	+
Heart <i>arrhythmia</i>	+	-
Histopathological		
Astrocytic gliosis	+	+
Vascular-type lesions and vascular inflammation	+	+
Elevated Ig levels	+	+

Table 2: Similarities between cerebral vasculitis-related symptoms reported to U.S. VAERS following vaccination with HPV vaccines Gardasil and Cervarix (see Table 3) in the post-licensure period (June 2006-September 2012) and symptoms experienced by Case 1 and Case 2 described in this report.

VAERS ID	Event Category	Adverse event description
425345-1	Hospitalized Serious (cerebral vasculitis)	This case was received from the Health Authority on 02-JUN-2011. Reference number: ADR 21077360. This case was medically confirmed. A 17 year old female patient received the second dose of GARDASIL (manufacturer, lot and batch number not reported) i.m. on 30-DEC-2008. On an unspecified date in March 2009, approximately three months post vaccination, the patient developed headaches, weakness and lack of coordination. The patient had the first dose of GARDASIL (manufacturer, lot and batch number not reported) on 02-DEC-2008. The patient was eventually admitted to hospital in 2009 for long periods of time and was extensively investigated. The patient had a rare cerebral vasculitis of unknown cause. This was steroid responsive but the patient was unable to speak, walk or coordinate her movements. The patient was fed through a percutaneous endoscopic gastrostomy and was cared for 24 hours a day. At the time of reporting, the patient had not yet recovered (also reported as unknown). The reporter stated that whilst it clearly could not be proven that the patient's illness was directly linked to GARDASIL vaccine she had a serious disability. The patient's illness was rare and unexplained and her parents were convinced that it was caused by the vaccine. The events were considered serious due to hospitalization and disability. Other business partner number included: E2011-03389. No further information is available.
338235-1	Hospitalized Serious (cerebral vasculitis)	Information has been received from the foreign Health Authorities (Reference no.: PEI2008021098), concerning a 17 year old female patient, who on 18-SEP-2007, was vaccinated with the first dose of GARDASIL (toleration was not reported); on 20-NOV-2007, was vaccinated with the second dose of GARDASIL (toleration not reported) and on 11-MAR-2008, was vaccinated with third dose of GARDASIL, intramuscularly (Lot # and injection site not reported). Starting mid-Jun-2008, the patient developed cerebral vasculitis with acute psychotic symptoms and seizures. Cerebral biopsy, performed on 26-AUG-2008, revealed astrocytic gliosis. Lab finding showed increased number of cells in cerebrospinal fluid (=CSF). Despite of therapies with cortisone, neuroleptics and antiepileptics, the patient only improved slowly from the severe organic brain syndrome with slowdown, cognitive disorders and emotional symptoms. The cause of cerebral vasculitis remained unexplained. The patient had not recovered.
396220-1	Life-threatening Serious (cerebral vasculitis)	Information has been received from a physician concerning her 15 year old daughter with no pertinent medical history or drug allergies who in September 2009, was vaccinated with a first dose of GARDASIL (lot # not reported). No concomitant medications were reported. It was reported that in September 2009, very soon after the injection of GARDASIL, the patient developed fatigue and nausea. When the patient was on leaving the physician's office she experienced syncope. The patient began having symptoms of high fever, headache and sore muscles. The patient was lethargic for months after she received GARDASIL. In June 2010 the patient had chest pain and went to the Emergency Room where she was diagnosed with anxiety. The EKG showed arrhythmias. The patient became weak and had to quit the Track Team at school. In June 2010 the patient was tired and lethargic and began to forget things. Approximately three weeks ago, in approximately August 2010, the patient developed a tremor in her left hand and she was unable to speak. The patient developed chronic seizures with chorea. On 08-AUG-2010 the patient was admitted to hospital. On 15-AUG-2010 the patient developed a stroke and was non verbal. The patient was diagnosed with drug induced systemic lupus erythematosus with chorea. It was reported that there was central nervous system (CNS) involvement and the patient had vasculitis of the brain. The physician did not report what type of diagnostic testing the patient had received. The patient was being treated with ten different medications reported as follows: intravenous immune globulin (IVIG), antibiotics, anti hypertensive medications due to kidney involvement and high doses of IV prednisone. The physician stated that today, on 17-AUG-2010, the patient was to begin chemotherapy with IV cytotoxin for a duration of 24 hours. Currently, the patient had her voice back and was able to move all of her extremities except the left arm. As of 16-AUG-2010 the patient had not recovered from drug induced systemic lupus erythematosus with chorea, anxiety and arrhythmias. The patient was presently in hospital. The reporter felt that drug induced systemic lupus erythematosus with chorea was related to therapy with GARDASIL. Drug induced systemic lupus erythematosus with chorea, anxiety and arrhythmias were considered to be disabling, another important medical event and immediately life-threatening. Additional information has been requested.
335698-1	Not Serious (cerebral vasculitis)	Information has been received from a physician, concerning a patient who was vaccinated with GARDASIL vaccine 0.5 ml, intramuscularly. The physician reported that after receiving the GARDASIL vaccine, about 2 months ago, the patient experienced cerebral vasculitis and seizures. The doctor was unsure if it was the first or second 0.5 ml dose. The doctor was not sure if the patient would be seeing a specialist about this AE. The outcome is unknown. The patient sought unspecified medical attention. Upon internal review, seizures were determined to be an other important medical event. Additional information has been requested.
436679-1	Hospitalized Serious (cerebral vasculitis)	Case received from the Health Authorities in a foreign country on 23-SEP-2011 under the reference number PP20110312: Case medically confirmed. A 14 year old female patient was vaccinated intramuscularly with the first and second doses of GARDASIL (batch number not reported) on 06-OCT-2010 and 15-DEC-2010. On 11-MAR-2011 she experienced vertigo and migraine during 15 to 18 hours. On 12-MAR-2011 brain MRI (magnetic resonance imaging) showed mild lesions on white substance hypersignal, and medullar MRI was normal. On 25-JUL-2011 brain MRI showed persistence of the periventricular white substance hypersignals, stable. The patient was seen in neurology consultation which revealed numerous non inflammatory but vascular-type lesions, and no evident diagnosis. The third dose of GARDASIL was not administered. The patient's hospitalization dates were not provided. At the time of reporting the patient had not recovered. The Health Authorities assessed the causal relationship between the reported reactions and vaccination as doubtful (C2 S1 L1) according to the foreign method of assessment. Other business partner numbers included: E2011-05715.

387696-1	Hospitalized Serious (vasculitis unspecified)	Information was obtained on request by the company from the agency via public case details form for the Pregnancy Registry for GARDASIL concerning a 20 year old female with a penicillin, yeast and tomatoes allergies and moderate asthma who on 01-JUN-2008 was vaccinated IM with a first dose of GARDASIL (lot number and site injection not reported). Concomitant therapy included ASMOL and SERETIDE ACCUHALER. It was reported that the patient was eight weeks pregnant at the time of vaccination. On 30-JUN-2008, the patient experienced red spotty rash developing on legs starting around the ankles. Within days it had spread and started to burn and go numb. After a week the patient legs were covered in severe welts and the swelling was so bad she could not walk. After she was admitted to the hospital, some lesions became infected and gangrenous. After wounds healed she was left with significant scarring on her legs. The patient was hospitalized and treated for autoimmune vasculitis. Infected and gangrenous lesions resolved with intravenous antibiotics and steroids (date unspecified). The agency considered that vasculitis was possibly related to therapy with GARDASIL. The original reporting source was not provided. No further information is available.
400182-1	Not Serious (vasculitis unspecified)	"Information has been received from a physician concerning a 18 year old patient who on 26-JAN-2009 was vaccinated with the third dose of GARDASIL. On approximately 26-MAY-2009 "four months later" she was sent to a rheumatologist. She developed some sort of autoimmune disease, elevated IGA levels, vasculitis and skin lesions. She was put on steroids and it was still unknown what actually happened. There is some inference that GARDASIL may have a possible connection since it was one of the things she had been on. The patient sought unspecified medical attention. The health professional contacted during telephone follow up could not supply the following information: patient name, date of birth, dates of vaccination, dose number (if applicable), lot number (if applicable), date of event, recovery status, hospital name (if applicable). Additional information has been requested."
374104-1	Not Serious (generalized vasculitis)	This case was reported by a regulatory authority (# 108179) and described the occurrence of generalized vasculitis in a 12-year-old female subject who was vaccinated with CERVARIX (GlaxoSmithKline). No concomitant medication was reported. On 6 October 2008 the subject received unspecified dose of CERVARIX (unknown route and injection site). On 10 October 2008, 4 days after vaccination with CERVARIX, the subject experienced generalized vasculitis. This case was assessed as medically serious by GSK. No treatment was reported. On 15 November 2008, the event was resolved. No further information is expected, the regulatory Authority has provided GSK with all the available information for the time being, if they ever get any further information they will send it to GSK.
452887-1	Not Serious (vasculitis unspecified)	This case was reported by a regulatory authority (GB-MHRA-EYC 00083098) and described the occurrence of vasculitis in a 13-year-old female subject who was vaccinated with CERVARIX. On an unspecified date the subject received unspecified dose of CERVARIX. At an unspecified time after vaccination with CERVARIX, the subject experienced vasculitis. The regulatory authority reported that the event was clinically significant (or requiring intervention). At the time of reporting the outcome of the event was unspecified. MHRA Verbatim Text: Vasculitis. Other medically significant: reporter considers serious.

Table 3: Sample of VAERS reports related to cases of vasculitis following HPV vaccination. The VAERS database [59] was searched using the following criteria: (1) Symptoms: vasculitis, vasculitis cerebral, vasculitis gastrointestinal, vasculitis necrotising; (2) Vaccine products: HPV2 (human papilloma virus bivalent), HPV4 (human papilloma virus types 6,11,16,18), HPV (human papilloma virus); (3) Event category: all events; (4) Territory: all locations; (5) Date vaccinated: 2006-2012 (HPV vaccine post-licensure period). A total of 40 events were reported to VAERS. Note however that the clinical presentation of vasculitis is highly variable with fluctuating signs and symptoms and it is thus probable that many cases remain unreported, undiagnosed and/or misdiagnosed.

invading foreign infectious agent (i.e., virus or bacteria) thus indicates an abnormal triggering of the immune response in which the immune attack is directed towards self-tissue. Such activation of the MAC in brain tissue specimens from Case 1 and Case 2 can therefore plausibly be explained by the receipt of the qHPV vaccine given that in both cases the autopsy examinations found no evidence of an alternative microbiological insult to explain the fatal outcomes. Moreover, prominent MAC immunoreactivity was also detected in cerebellar Purkinje cells and neurons in various areas of the brain, including the hippocampus. These results will be presented and discussed in greater detail in a separate publication.

In addition, we detected intense MMP-9 immunostaining in the vascular wall and the perivascular extracellular matrix (ECM) in brain tissue specimens from both cases. The vascular wall MMP-9 immunostaining pattern closely coincided with that of HPV-16L1 and C1q (Figures 3 and 4). This finding again corroborates our suggestion of an immune-triggered vasculopathy as an underlying cause for the fatal outcomes in both cases following qHPV vaccination. Indeed, MMP-9 is one of the key proteolytic enzymes involved in progression of inflammatory infiltrates and vessel and ECM destruction in vasculitis [41-43]. Elevated MMP-9 expression is strongly associated with neuroimmune vasculopathies and diverse severe inflammatory nervous system pathologies, including ischemic nerve damage in SLE [41], autoimmune demyelinating syndromes, ischemia and stroke [72,73]. MMPs are also prominently elevated in neuropathic pain syndromes such as migraine headaches [74,75]. In this regard, we note that headaches are one of the most frequently reported symptoms post-HPV vaccination (Table 4) and could be due to an underlying undiagnosed or misdiagnosed cerebral vasculitis.

Moreover, MMP-2 and MMP-9 have been shown to induce blood-brain barrier breakdown and to facilitate leukocyte extravasation in experimental bacterial meningitis [76] and other models of

neuroinflammation [77,78] of the central and peripheral nervous systems. In particular, in bacterial meningitis, acute breakdown of the blood-brain barrier, intrathecal production of pro-inflammatory cytokines and accumulation of blood derived leukocytes in the cerebrospinal fluid lead to brain edema, cerebral vasculitis, and ultimately permanent neuronal injury. An overactive immune response of the host, rather than the bacterial pathogen per se, is thought to be the cause of neuronal injury, resulting in permanent neurological sequelae [43,79]. In this regard, it is important to re-emphasize the fact that vaccines, designed to hyper-stimulate the immune response (owing to the action of immune adjuvants), appear to carry an inherent risk for serious autoimmune disorders affecting the CNS [17,80-82]. Based on exhaustive investigations of post-vaccination induced autoimmune phenomena, Cohen, Carvalho and Shoenfeld have concluded that, "it seems that vaccines have a predilection to affect the nervous system" [1,83].

The obvious limitations of our study are that the tissues examined represent two individuals against which there were no control samples. For this reason, we could not obtain a quantitative measure of immunoreactivity. We aim in the future to further corroborate our findings by examining brain tissues from other cases of sudden and unexplained death following HPV vaccination, as well as control brain tissue from age-matched individuals who clearly died from non-vaccination related causes. Nonetheless, the marked resemblance in immunostaining patterns for all immunohistological markers in brain tissue specimens in the present two cases (i.e., compare Figures 1-4), as well as the similarity between their symptoms and those noted on VAERS reports related to post-HPV vaccination vasculopathies (some of which were medically ascertained cases; Tables 2 and 3), strongly support our present conclusions.

Conclusion

Any medicinal product (including vaccines) carries some risk of

Cerebral vasculitis-related symptoms reported to U.S. VAERS post-HPV vaccination	# reports	% total
Syncope	3127	14.2
Dizziness	3012	13.7
Headaches, migraines	2385	10.9
Nausea	2147	9.8
Fatigue	1100	5
Seizures	923	4.2
Tremors	531	2.4
Psychotic symptoms, anxiety	256	1.2
Cognitive disorder, amnesia, memory impairment	164	0.8
Vasculitis cerebral	5	0.02

Table 4: Cerebral vasculitis and related symptoms reported to U.S. VAERS following vaccination with HPV vaccines Gardasil and Cervarix in the post-licensure period (June 2006-September 2012).

The VAERS database [59] was searched using the following criteria: (1) Symptoms: syncope, dizziness, headaches, migraines, nausea, fatigue, seizures, tremors, psychotic symptoms, anxiety, cognitive disorder, amnesia, memory impairment and vasculitis cerebral; (2) Vaccine products: HPV2 (human papilloma virus bivalent), HPV4 (human papilloma virus types 6,11,16,18), HPV (human papilloma virus); (3) Event category: all events; (4) Territory: United States; (5) Date vaccinated: 2006-2012.

adverse effects. However, unlike most medicinal products, vaccines are often administered to otherwise healthy individuals and this fact, according to the FDA, places significant emphasis on their safety [84]. The proper understanding of a true risk from vaccines is thus crucial for avoiding unnecessary ADRs [19]. In this regard, the fact that to date no solid tests or criteria have been established to determine whether adverse events are causally linked to vaccinations [6,16] should be a cause for concern.

In recent years it has become increasingly clear that vaccines may be a triggering factor for severe neurological manifestations of autoimmune etiology [1-13]. Some of these autoimmune phenomena may be explained by molecular mimicry whereby an antigen of a recombinant vaccine (i.e., HPV or hepatitis B vaccine) or of a live, attenuated virus (i.e., MMR) may resemble a host antigen and trigger autoimmunity [5,6,83]. Owing to their structural resemblance, antibodies and auto-reactive T cells not only destroy the invading pathogen but also attack the host tissue. The data from the present study not only validate the molecular mimicry hypothesis of vaccine-induced autoimmune diseases, but also further expand on the proposed pathway, which most likely begins with the passage of vaccine-derived HPV-16L1 antibodies across the blood-brain barrier and the choroid plexus. Once in the CNS, some of these antibodies bind to neuronal host-antigen(s) due to molecular mimicry, such as vascular endothelial and/or smooth muscle cells. This further leads to a classical antibody-dependent complement pathway activation (C1q and MAC), resulting in destruction of blood vessel integrity, hemorrhages and ischemic tissue injury. The resultant blood-brain barrier breakdown allows further nondiscriminatory passage of immune cells and vaccine-derived immune complexes into the brain thus perpetuating the HPV vaccine triggered neurodestructive autoimmune process. The HPV-16L1 VLPs appear to contribute to this aberrant immune process by invading the CNS (most likely via a macrophage-dependent Trojan horse mechanism), and depositing on the walls of cerebral blood vessels.

Cerebral vasculitis is a serious disease which typically results in fatal outcomes when undiagnosed and left untreated [37]. The fact that many of the symptoms reported to VAERS following HPV vaccination are indicative of cerebral vasculitis, but are unrecognized as such (i.e., intense persistent migraines, syncope, seizures, tremors and tingling, myalgia, locomotor abnormalities, psychotic symptoms and cognitive deficits; Table 4) is thus a serious concern in light of the present findings. In particular, the fact that positive cerebral blood vessel wall

immunoreactivity was observed with HPV-16L1 and not with HPV-18L1 antibody (Figure 1) suggests that HPV vaccines containing HPV-16L1 VLPs (including Gardasil and Cervarix) pose an inherent risk for triggering potentially fatal autoimmune vasculopathies and are therefore inherently unsafe for some individuals. Exactly which individuals might be more prone to developing a serious ADR following HPV vaccination is currently unknown. It is also unknown whether HPV vaccination can actually prevent cervical cancer cases since the current optimistic surrogate-marker based extrapolations have not been validated and appear to have arisen primarily from significant misinterpretation of existing data [25,85]. Because the HPV vaccination programme has global coverage, the long-term health of many women may be at risk against still unknown vaccine benefits. In conclusion, any case of sudden unexpected death occurring after HPV or other vaccinations should always undergo an exhaustive immunohistochemical study according to the methods presented in this report.

Acknowledgments

This work was supported by the Dwoskin, Lotus and Katlyn Fox Family Foundations. We are very grateful to Ingrid Barta from the University of British Columbia Department of Pathology and Laboratory Medicine for technical support.

References

- de Carvalho JF, Shoenfeld Y (2008) Status epilepticus and lymphocytic pneumonitis following hepatitis B vaccination. *Eur J Intern Med* 19: 383-385.
- Souayah N, Michas-Martin PA, Nasar A, Krivitskaya N, Yacoub HA, et al. (2011) Guillain-Barre syndrome after Gardasil vaccination: data from Vaccine Adverse Event Reporting System 2006-2009. *Vaccine* 29: 886-889.
- Souayah N, Nasar A, Suri MF, Qureshi AI (2009) Guillain-Barre syndrome after vaccination in United States: data from the Centers for Disease Control and Prevention/Food and Drug Administration Vaccine Adverse Event Reporting System (1990-2005). *J Clin Neuromuscul Dis* 11: 1-6.
- Shoenfeld Y, Aron-Maor A (2000) Vaccination and autoimmunity-'vaccinosis': a dangerous liaison? *J Autoimmun* 14: 1-10.
- de Carvalho JF, Pereira RM, Shoenfeld Y (2008) Systemic polyarteritis nodosa following hepatitis B vaccination. *Eur J Intern Med* 19: 575-578.
- Agmon-Levin N, Paz Z, Israeli E, Shoenfeld Y (2009) Vaccines and autoimmunity. *Nat Rev Rheumatol* 5: 648-652.
- Zafir Y, Agmon-Levin N, Paz Z, Shilton T, Shoenfeld Y (2012) Autoimmunity following Hepatitis B vaccine as part of the spectrum of 'Autoimmune (Auto-inflammatory) Syndrome induced by Adjuvants' (ASIA): analysis of 93 cases. *Lupus* 21: 146-152.
- Konstantinou D, Paschalis C, Maraziotis T, Dimopoulos P, Bassaris H, et al. (2001) Two episodes of leukoencephalitis associated with recombinant hepatitis B vaccination in a single patient. *Clin Infect Dis* 33: 1772-1773.
- Aron-Maor A, Shoenfeld Y (2001) Vaccination and systemic lupus erythematosus: the bidirectional dilemmas. *Lupus* 10: 237-240.
- Aydin H, Ozgul E, Agildere AM (2010) Acute necrotizing encephalopathy secondary to diphtheria, tetanus toxoid and whole-cell pertussis vaccination: diffusion-weighted imaging and proton MR spectroscopy findings. *Pediatr Radiol* 40: 1281-1284.
- Mendoza Plasencia Z, González López M, Fernández Sanfiel ML, Muñiz Montes JR (2010) Acute disseminated encephalomyelitis with tumefactive lesions after vaccination against human papillomavirus. *Neurologia* 25: 58-59.
- Chang J, Campagnolo D, Vollmer TL, Bomprezzi R (2010) Demyelinating disease and polyvalent human papilloma virus vaccination. *J Neurol Neurosurg Psychiatry* 82: 1296-1298.
- Authier FJ, Cherin P, Creange A, Bonnotte B, Ferrer X, et al. (2001) Central nervous system disease in patients with macrophagic myofasciitis. *Brain* 124: 974-983.
- Silvers LE, Ellenberg SS, Wise RP, Varricchio FE, Mootrey GT, et al. (2001) The epidemiology of fatalities reported to the vaccine adverse event reporting system 1990-1997. *Pharmacoepidemiol Drug Saf* 10: 279-285.

15. Miravalle A, Biller J, Schnitzler E, Bonwit A (2010) Neurological complications following vaccinations. *Neurol Res* 32: 285-292.
16. Zinka B, Penning R (2006) Unexplained cases of sudden infant death shortly after hexavalent vaccination. Letter to Editor. Response to the comment by H.J. Schmitt et al. *Vaccine* 24: 5785-5786.
17. Tomljenovic L, Shaw CA (2012) Mechanisms of aluminum adjuvant toxicity in pediatric populations. *Lupus* 21: 223-230.
18. Couette M, Boisse MF, Maison P, Brugieres P, Cesaro P, et al. (2009) Long-term persistence of vaccine-derived aluminum hydroxide is associated with chronic cognitive dysfunction. *J Inorg Biochem* 103: 1571-1578.
19. Tomljenovic L, Shaw CA (2012) "One-size fits all"? *Vaccine* 30: 2040.
20. Ottaviani G, Lavezzi AM, Maturri L (2006) Sudden infant death syndrome (SIDS) shortly after hexavalent vaccination: another pathology in suspected SIDS? *Virchows Arch* 448: 100-104.
21. U.S. Food and Drug Administration (FDA) News Release. June 8, 2006. FDA Licenses New Vaccine for Prevention of Cervical Cancer and Other Diseases in Females Caused by Human Papillomavirus. Rapid Approval Marks Major Advancement in Public Health. (internet)
22. U.S. Food and Drug Administration Vaccines and Related Biological Products Advisory Committee (VRBPAC) Background Document: Gardasil™ HPV Quadrivalent Vaccine. May 18, 2006 VRBPAC Meeting. (internet)
23. Chao C, Klein NP, Velicer CM, Sy LS, Slezak JM, et al. (2011) Surveillance of autoimmune conditions following routine use of quadrivalent human papillomavirus vaccine. *J Intern Med* 271: 193-203.
24. Gostin LO (2011) Mandatory HPV vaccination and political debate. *JAMA* 306: 1699-1700.
25. Tomljenovic L, Shaw CA, Spinosa JP (2012) Human Papillomavirus (HPV) Vaccines as an Option for Preventing Cervical Malignancies: (How) Effective and Safe? *Curr Pharm Des*.
26. Tomljenovic L, Shaw CA (2011) Human papillomavirus (HPV) vaccine policy and evidence-based medicine: Are they at odds? *Ann Med*.
27. Tomljenovic L, Shaw CA (2012) No autoimmune safety signal after vaccination with quadrivalent HPV vaccine Gardasil? *J Intern Med*.
28. Tomljenovic L, Shaw CA (2012) Who profits from uncritical acceptance of biased estimates of vaccine efficacy and safety? *Am J Public Health* 102: e13-e14.
29. Wildemann B, Jarius S, Hartmann M, Regula JU, Hametner C (2009) Acute disseminated encephalomyelitis following vaccination against human papilloma virus. *Neurology* 72: 2132-2133.
30. DiMario FJ Jr, Hajjar M, Ciesielski T (2010) A 16-year-old girl with bilateral visual loss and left hemiparesis following an immunization against human papilloma virus. *J Child Neurol* 25: 321-327.
31. Pugno G, Ysebaert L, Bagheri H, Montastruc JL, Laurent G (2009) Immune thrombocytopenic purpura following human papillomavirus vaccination. *Vaccine* 27: 3690.
32. Melo Gomes S, Glover M, Malone M, Brogan P (2012) Vasculitis following HPV immunization. *Rheumatology (Oxford)*.
33. McCarthy JE, Filiano J (2009) Opsoclonus Myoclonus after human papilloma virus vaccine in a pediatric patient. *Parkinsonism Relat Disord* 15: 792-794.
34. Della Corte C, Carlucci A, Francalanci P, Alisi A, Nobili V (2011) Autoimmune hepatitis type 2 following anti-papillomavirus vaccination in a 11-year-old girl. *Vaccine* 29: 4654-4656.
35. Sutton I, Lahoria R, Tan I, Clouston P, Barnett M (2009) CNS demyelination and quadrivalent HPV vaccination. *Mult Scler* 15: 116-119.
36. Savage CO, Ng YC (1986) The aetiology and pathogenesis of major systemic vasculitides. *Postgrad Med J* 62: 627-636.
37. Younger DS (2004) Vasculitis of the nervous system. *Curr Opin Neurol* 17: 317-336.
38. Moritani T, Hiwatashi A, Shrier DA, Wang HZ, Numaguchi Y, et al. (2004) CNS vasculitis and vasculopathy: efficacy and usefulness of diffusion-weighted echoplanar MR imaging. *Clin Imaging* 28: 261-270.
39. Moore PM, Richardson B (1998) Neurology of the vasculitides and connective tissue diseases. *J Neurol Neurosurg Psychiatry* 65:10-22.
40. Lienert C, Sturzenegger M (2008) [Cerebral vasculitis]. *Ther Umsch* 65: 259-263.
41. Mawrin C, Brunn A, Röcken C, Schröder JM (2003) Peripheral neuropathy in systemic lupus erythematosus: pathomorphological features and distribution pattern of matrix metalloproteinases. *Acta Neuropathol* 105: 365-372.
42. Segarra M, García-Martínez A, Sánchez M, Hernández-Rodríguez J, Lozano E, et al. (2007) Gelatinase expression and proteolytic activity in giant-cell arteritis. *Ann Rheum Dis* 66: 1429-1435.
43. Leppert D, Leib SL, Grygar C, Miller KM, Schaad UB, et al. (2000) Matrix metalloproteinase (MMP)-8 and MMP-9 in cerebrospinal fluid during bacterial meningitis: association with blood-brain barrier damage and neurological sequelae. *Clin Infect Dis* 31: 80-84.
44. Gherardi RK, Authier FJ (2012) Macrophagic myofasciitis: characterization and pathophysiology. *Lupus* 21: 184-189.
45. Sekula RF Jr, Marchan EM, Baghai P, Jannetta PJ, Quigley MR (2006) Central brain herniation secondary to fulminant acute disseminated encephalomyelitis: implications for neurosurgical management. Case report. *J J Neurosurg* 105: 472-474.
46. Block ML, Hong JS (2005) Microglia and inflammation-mediated neurodegeneration: multiple triggers with a common mechanism. *Prog Neurobiol* 76: 77-98.
47. Block ML, Zecca L, Hong JS (2007) Microglia-mediated neurotoxicity: uncovering the molecular mechanisms. *Nat Rev Neurosci* 8: 57-69.
48. Prat A, Biernacki K, Wosik K, Antel JP (2001) Glial cell influence on the human blood-brain barrier. *Glia* 36:145-155.
49. Del Bigio MR, Becker LE (1994) Microglial aggregation in the dentate gyrus: a marker of mild hypoxic-ischaemic brain insult in human infants. *Neuropathol Appl Neurobiol* 20: 144-151.
50. Shaw CA, Petrik MS (2009) Aluminum hydroxide injections lead to motor deficits and motor neuron degeneration. *J Inorg Biochem* 103: 1555-1562.
51. Fu M, Omay SB, Morgan J, Kelley B, Abbed, et al. (2011) Primary Central Nervous System Vasculitis Presenting as Spinal Subdural Hematoma. *World Neurosurg* 78:192.e5-e6.
52. Cekinmez EK, Cengiz N, Erol I, Kizilkiliç O, Uslu Y (2009) Unusual cause of acute neurologic deficit in childhood: primary central nervous system vasculitis presenting with basilar arterial occlusion. *Childs Nerv Syst* 25: 133-136.
53. Alexander JJ, Bao L, Jacob A, Kraus DM, Holers VM, et al. (2003) Administration of the soluble complement inhibitor, Crry-Ig, reduces inflammation and aquaporin 4 expression in lupus cerebritis. *Biochim Biophys Acta* 1639: 169-176.
54. Zaas A, Scheel P, Venbrux A, Hellmann DB (2001) Large artery vasculitis following recombinant hepatitis B vaccination: 2 cases. *J Rheumatol* 28: 1116-1120.
55. Le Hello C, Cohen P, Bousser MG, Letellier P, Guillemin L (1999) Suspected hepatitis B vaccination related vasculitis. *J Rheumatol* 26: 191-194.
56. De Keyser F, Naeyaert JM, Hindryckx P, Elewaut D, Verplancke P, et al. (2000) Immune-mediated pathology following hepatitis B vaccination. Two cases of polyarteritis nodosa and one case of pityriasis rosea-like drug eruption. *Clin Exp Rheumatol* 18: 81-85.
57. Bourgeois AM, Dore MX, Croue A, Leclech C, Verret JL (2003) [Cutaneous polyarteritis nodosa following hepatitis B vaccination]. *Ann Dermatol Venerol* 130: 205-207.
58. Olsson SE, Villa LL, Costa RL, Petta CA, Andrade RP, et al. (2007) Induction of immune memory following administration of a prophylactic quadrivalent human papillomavirus (HPV) types 6/11/16/18 L1 virus-like particle (VLP) vaccine. *Vaccine* 25: 4931-4939.
59. US Centers for Disease Control and Prevention (CDC) WONDER VAERS Request. (internet)
60. Watanabe N, Aikusa B, Park SY, Ohno H, Fossati L, et al. (1999) Mast cells induce autoantibody-mediated vasculitis syndrome through tumor necrosis factor production upon triggering Fcγ receptors. *Blood* 94: 3855-3863.
61. Lister KJ, Hickey MJ (2006) Immune complexes alter cerebral microvessel permeability: roles of complement and leukocyte adhesion. *Am J Physiol Heart Circ Physiol* 291: H694-H704.

62. Stokol T, O'Donnell P, Xiao L, Knight S, Stavrakis G, et al. (2004) C1q governs deposition of circulating immune complexes and leukocyte Fcγ receptors mediate subsequent neutrophil recruitment. *J Exp Med* 200: 835-846.
63. Yakushiji Y, Mizuta H, Kurohara K, Onoue H, Okada R, et al. (2007) Vasculitic neuropathy in a patient with hereditary C1 inhibitor deficiency. *Arch Neurol* 64: 731-733.
64. D'Andrea MR (2005) Evidence that immunoglobulin-positive neurons in Alzheimer's disease are dying via the classical antibody-dependent complement pathway. *Am J Alzheimers Dis Other Dement* 20:144-150.
65. Chen M, Daha MR, Kallenberg CG (2009) The complement system in systemic autoimmune disease. *J Autoimmun* 34: J276-286.
66. Shingu M, Yoshioka K, Nobunaga M, Motomatu T (1989) C1q binding to human vascular smooth muscle cells mediates immune complex deposition and superoxide generation. *Inflammation* 13: 561-569.
67. Brogan PA, Shah V, Klein N, Dillon MJ (2004) Vβ-restricted T cell adherence to endothelial cells: a mechanism for superantigen-dependent vascular injury. *Arthritis Rheum* 50: 589-597.
68. Stemme S, Fager G, Hansson GK (1990) MHC class II antigen expression in human vascular smooth muscle cells is induced by interferon-γ and modulated by tumour necrosis factor and lymphotoxin. *Immunology* 69: 243-249.
69. van Beek J, Elward K, Gasque P (2003) Activation of complement in the central nervous system: roles in neurodegeneration and neuroprotection. *Ann N Y Acad Sci* 992: 56-71.
70. Salehen N, Stover C (2008) The role of complement in the success of vaccination with conjugated vs. unconjugated polysaccharide antigen. *Vaccine* 26: 451-459.
71. Reddy ST, van der Vlies AJ, Simeoni E, Angeli V, Randolph GJ, et al. (2007) Exploiting lymphatic transport and complement activation in nanoparticle vaccines. *Nat Biotechnol* 25: 1159-1164.
72. Fujioka H, Daiyo Y, Yasunaga K, Emoto K (2012) Neural functions of matrix metalloproteinases: plasticity, neurogenesis, and disease. *Biochem Res Int* .
73. Wu H, Zhang Z, Hu X, Zhao R, Song Y, et al. (2010) Dynamic changes of inflammatory markers in brain after hemorrhagic stroke in humans: a postmortem study. *Brain Res* 1342: 111-117.
74. Leira R, Sobrino T, Rodríguez-Yáñez M, Blanco M, Arias S, et al. (2007) Mmp-9 immunoreactivity in acute migraine. *Headache* 47: 698-702.
75. Bernecker C, Pailer S, Kieslinger P, Horejsi R, Möller R, et al. (2010) Increased matrix metalloproteinase activity is associated with migraine and migraine-related metabolic dysfunctions. *Eur J Neurol* 18: 571-576.
76. Paul R, Lorenz S, Koedel U, Sporer B, Vogel U, et al. (1998) Matrix metalloproteinases contribute to the blood-brain barrier disruption during bacterial meningitis. *Ann Neurol* 44: 592-600.
77. Mun-Bryce S, Rosenberg GA (1998) Gelatinase B modulates selective opening of the blood-brain barrier during inflammation. *Am J Physiol* 274: R1203-1211.
78. Gijbels K, Galarzy RE, Steinman L (1994) Reversal of experimental autoimmune encephalomyelitis with a hydroxamate inhibitor of matrix metalloproteinases. *J Clin Invest* 94: 2177-2182.
79. Pfister HW, Scheld WM (1997) Brain injury in bacterial meningitis: therapeutic implications. *Curr Opin Neurol* 10: 254-259.
80. Shoenfeld Y, Agmon-Levin N (2011) 'ASIA' - Autoimmune/inflammatory syndrome induced by adjuvants. *J Autoimmun* 36: 4-8.
81. Israeli E, Agmon-Levin N, Blank M, Shoenfeld Y (2009) Adjuvants and autoimmunity. *Lupus* 18: 1217-1225.
82. Quiroz-Rothe E, Ginel PJ, Pérez J, Lucena R, Rivero JLL (2005) Vaccine-associated acute polyneuropathy resembling Guillain-Barré syndrome in a dog. *EJCAP* 15.
83. Cohen AD, Shoenfeld Y (1996) Vaccine-induced autoimmunity. *J Autoimmun* 9: 699-703.
84. U.S. Food and Drug Administration (2002) Workshop on Non-clinical Safety Evaluation of Preventative Vaccines: Recent Advances and Regulatory Considerations. (internet)
85. Gerhardus A, Razum O (2010) A long story made too short: surrogate variables and the communication of HPV vaccine trial results. *J Epidemiol Community Health* 64: 377-378.

Submit your next manuscript and get advantages of OMICS Group submissions

Unique features:

- User friendly/feasible website-translation of your paper to 50 world's leading languages
- Audio Version of published paper
- Digital articles to share and explore

Special features:

- 200 Open Access Journals
- 15,000 editorial team
- 21 days rapid review process
- Quality and quick editorial, review and publication processing
- Indexing at PubMed (partial), Scopus, DOAJ, EBSCO, Index Copernicus and Google Scholar etc
- Sharing Option: Social Networking Enabled
- Authors, Reviewers and Editors rewarded with online Scientific Credits
- Better discount for your subsequent articles

Submit your manuscript at: <http://www.omicsonline.org/submit/>